


Slide 1

# Skeletal System

**BLISS Harry Bliss**



©2007 Harry Bliss. Distributed by Tribune Media Services, Inc. 8/25

www.harrybliss.com


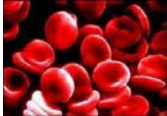


"Sofia, right? You hung out in the back of Professor Dillof's anatomy lectures."

The cartoon depicts a skeleton in a suit and glasses, holding a drink, engaged in conversation with a woman named Sofia at a social event. Other people are visible in the background. The artist's signature 'H. Bliss' is in the bottom right corner of the illustration.

Slide 2

## Functions of the Bones

- Support
- Protection
- Movement
- Storage
- Blood cell formation

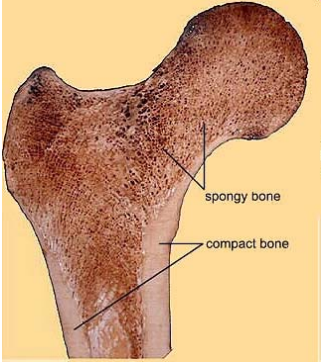


The slide illustrates the functions of bones with four images: a wooden frame representing support, a warehouse representing protection, a microscopic view of red blood cells representing blood cell formation, and a full human skeleton representing movement.

Slide 3

## Classification of Bones by Type

1. Compact
  - dense
  - looks smooth and homogeneous
2. Spongy
  - small needlelike pieces of bone
  - lots of open space

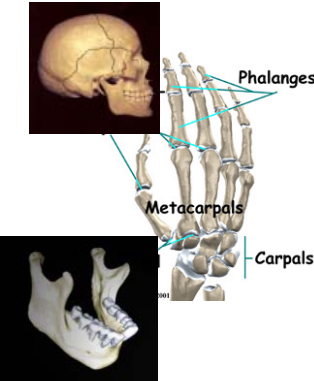


The image shows a cross-section of a bone with two distinct regions. The outer layer is labeled 'compact bone' and has a smooth, uniform appearance. The inner part is labeled 'spongy bone' and has a porous, porous appearance with many small openings.

Slide 4

## Classification of Bones by Shape

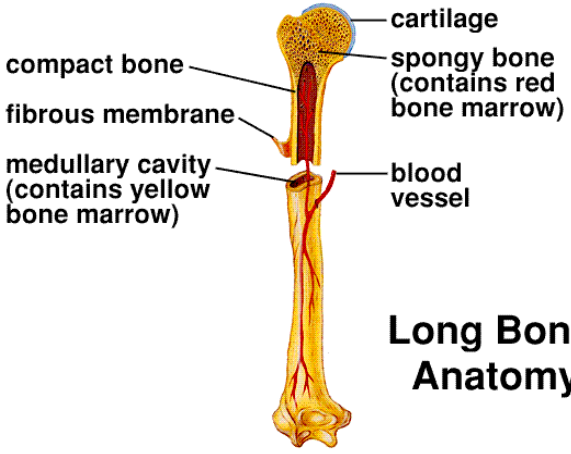
1. Long bone
  - humerus of arm
2. Short bones
  - carpals of wrist
3. Flat bone
  - parietal bone of skull
4. Irregular bone
  - vertebra



The image contains three anatomical illustrations. On the left, a lateral view of a human skull is shown, with a line pointing to the parietal bone. In the center, a humerus is shown in a vertical orientation. On the right, a hand skeleton is shown from a dorsal view, with lines pointing to the phalanges, metacarpals, and carpals.

Slide 5

Sylvia S. Mader, Inquiry into Life, 9th edition. Copyright © 1997 The McGraw-Hill Companies, Inc. All rights reserved.




**Long Bone Anatomy**

The diagram shows a long bone in a vertical orientation. Labels on the left side point to the cartilage at the top, the compact bone shaft, the fibrous membrane covering the shaft, and the medullary cavity (containing yellow bone marrow). Labels on the right side point to the spongy bone at the top (containing red bone marrow) and a blood vessel within the shaft.

Slide 6

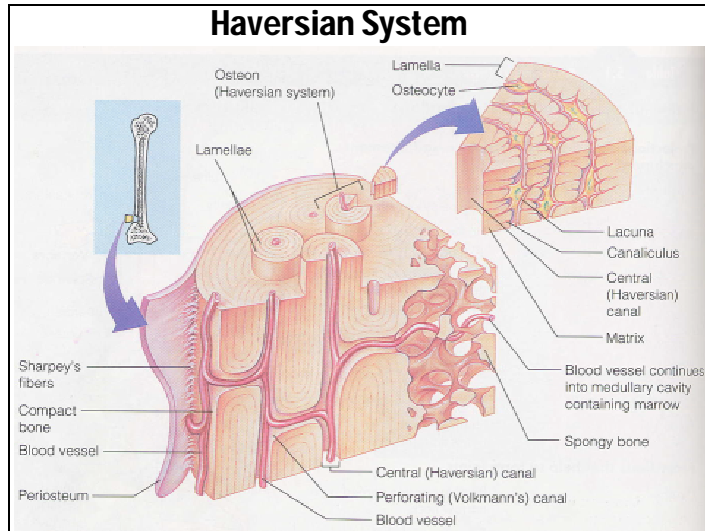
## Compact Bone

- Haversian system (osteon)
  - Haversian canal
  - Lamellae
  - Lacunae
  - Osteocyte
  - Canaliculi

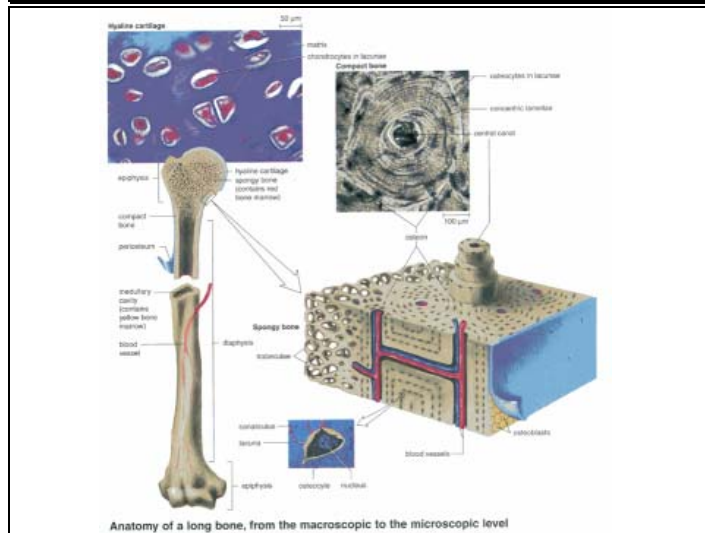


The image shows a cross-section of compact bone. It features a central Haversian canal containing a red blood vessel. Surrounding this canal are concentric layers of bone tissue called lamellae. Small spaces between the lamellae are called lacunae, which contain osteocytes. Fine canaliculi connect the osteocytes to each other and to the Haversian canal.

Slide 7



Slide 8



Slide 9

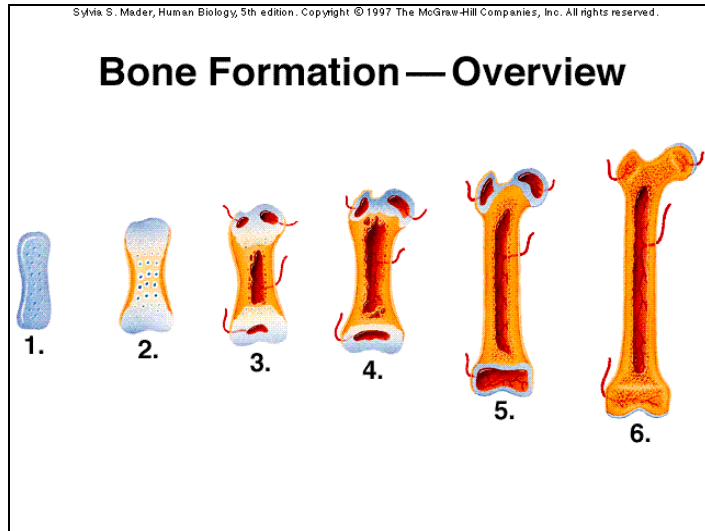
## Bone Formation, Growth, and Remodeling

**Ossification - process of bone formation**

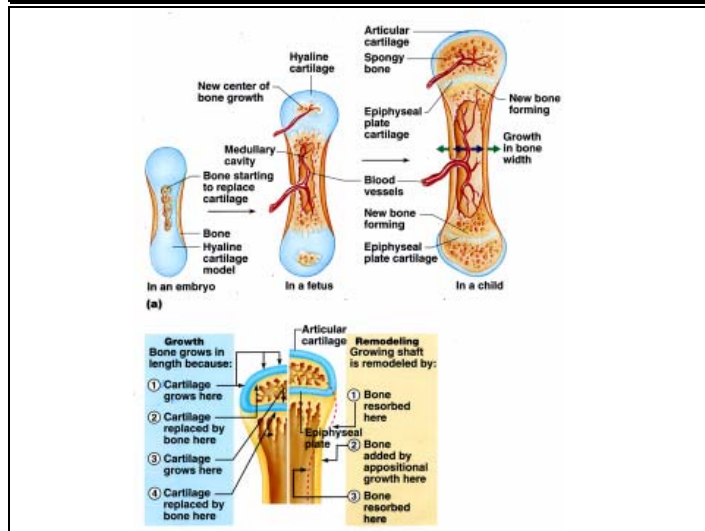
**Three types of bone cells**

1. **Osteocytes - mature bone cells**
2. **Osteoblasts - bone-forming cells**
3. **Osteoclasts - bone-destroying cells**

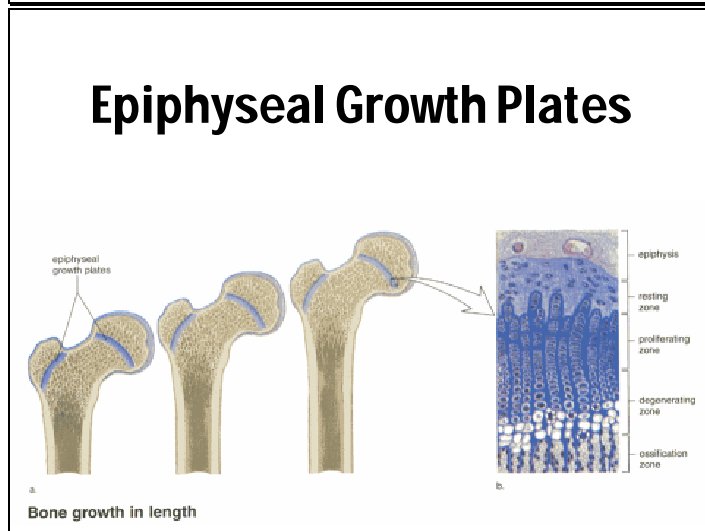
Slide 10



Slide 11



Slide 12

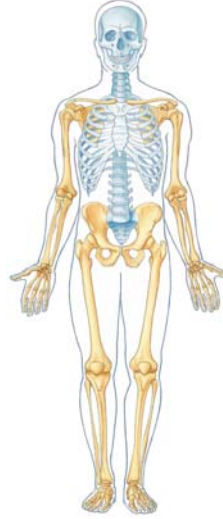

Slide 13

## Divisions of the Human Skeleton

Two divisions

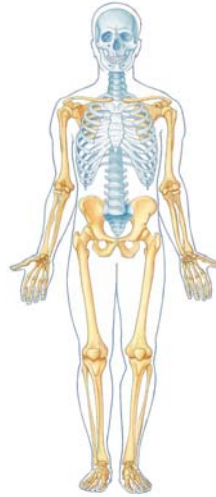1. Axial
2. Appendicular



Slide 14

## Axial Skeleton

- Skull
- Vertebrae
- Ribs
- Sternum

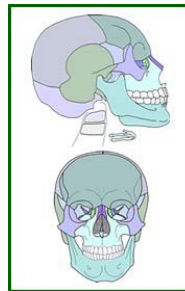

Slide 15

## The Skull

Two sets of bones

1. Cranium
2. Facial bones



**Sutures** – interlocking immovable joints

Slide 16

## Cranial Bones

**8 large flat bones**

**1 – frontal bone**

**2 – parietal bones**

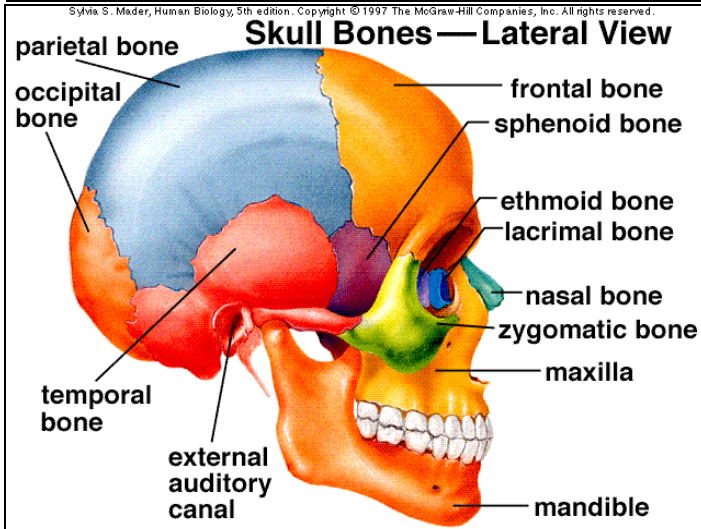
**1 – occipital bone**

**2 – temporal bones**

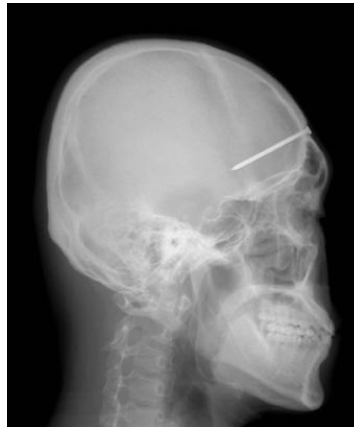**1 – sphenoid bone**

**1 – ethmoid bone**

Slide 17

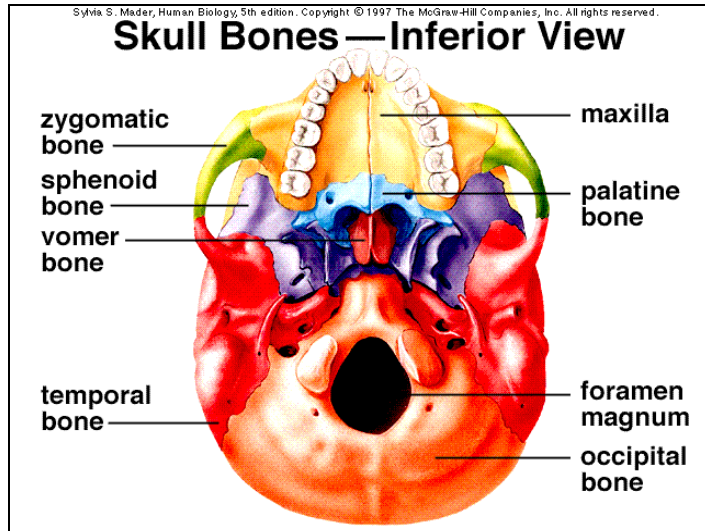


Slide 18

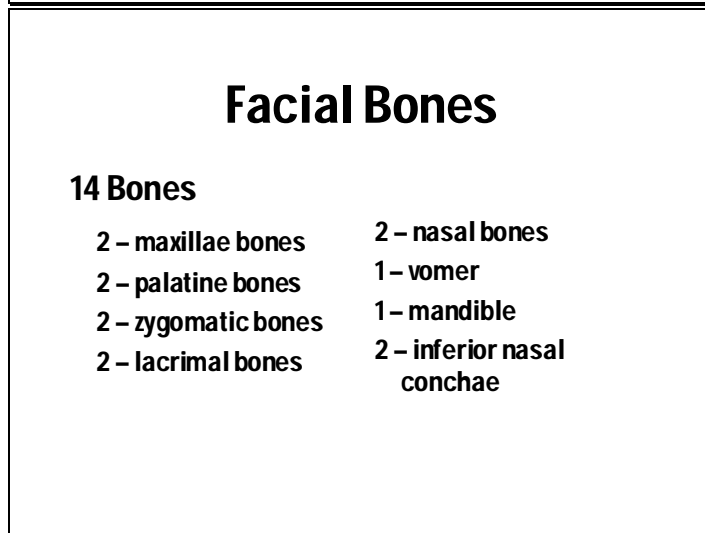


This X-ray picture shows a 5-centimeter nail stuck in an unidentified patient's skull Thursday, Dec. 2, 2004. According to the hospital, doctors found the nail after the man came to the hospital, complaining about a severe headache. They speculate that the nail stuck in the man's head four years ago in an accident but the man didn't know about it. The nail was removed in a surgery last Saturday. (AP Photo/Yonhap).

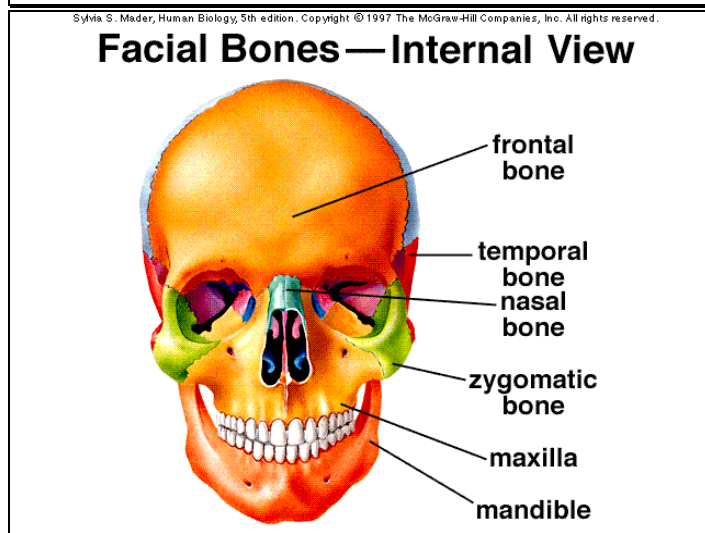
Slide 19



Slide 20

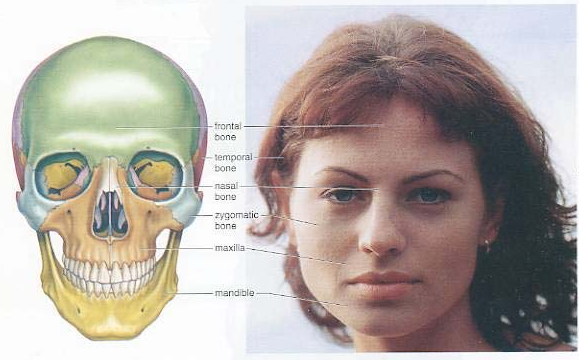


Slide 21



Slide 22

## Facial Bones & Your Face

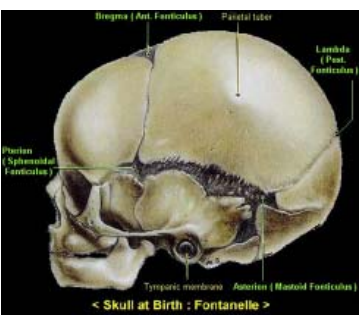


Bones of the face

Slide 23

## The Infant Skull

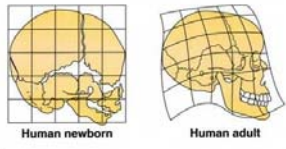
- **Fontanels**
  1. Anterior (frontal)
  2. Sphenoid (anterolateral)
  3. Posterior (occipital)
  4. Mastoid (posterolateral)
- **Functions**



< Skull at Birth : Fontanelle >

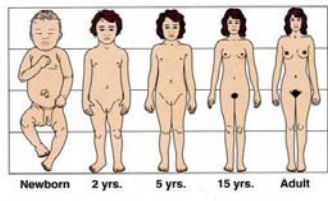
Slide 24

## Infant vs Adult



Human newborn      Human adult

- face : cranium



Newborn    2 yrs.    5 yrs.    15 yrs.    Adult

- skull : body length
- newborn skeleton

Copyright © 2003 Pearson Education, Inc., publishing as Benjamin Cummings.

Slide 25

# Vertebral Column

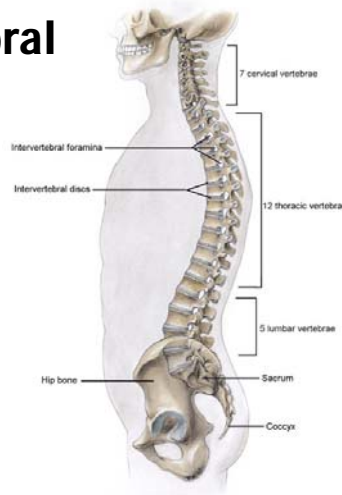
## Characteristics

- 26 irregular bones (originally 33)
- Surrounds and protects spinal cord
- top
- NOT rigid
- curves

Slide 26

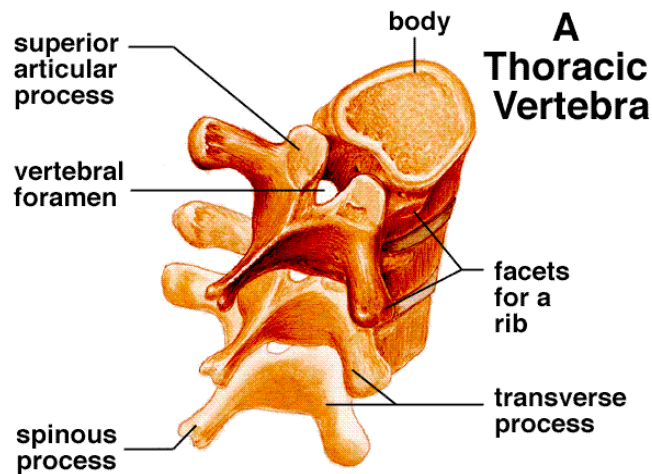
## Regions of Vertebral Column

- Cervical (7)
  - Atlas
  - Axis
- Thoracic (12)
- Lumbar (5)
- Sacral (5 fused)
- Coccygeal (4 vestigial)
  - Coccyx



Slide 27

Sylvia S. Mader, Human Biology, 5th edition. Copyright © 1997 The McGraw-Hill Companies, Inc. All rights reserved.

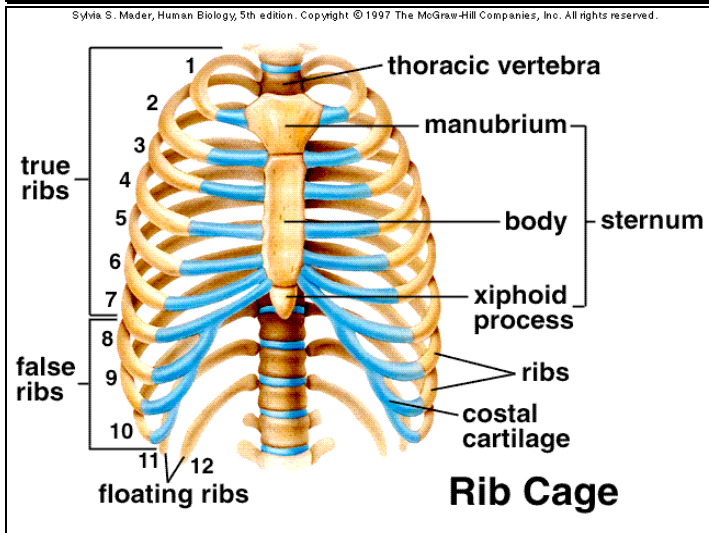


Slide 28

## Intervertebral discs

- **Function:**
  - cushion/shock absorber
- **Composition:**
  - fibrocartilage

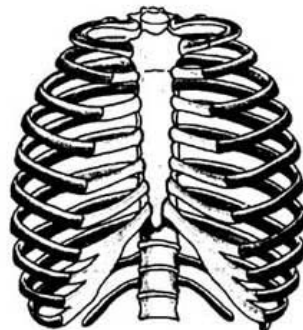
Slide 29



Slide 30

## Ribs

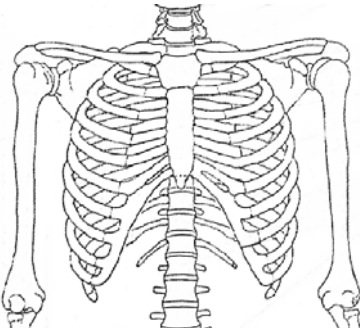
- **"True" ribs (7 pairs)**
  - Costal cartilage
- **"False" ribs (5 pairs)**
  - "Floating" ribs (2 pairs)
- **Sternum (breastbone)**



Slide 31

## Rib Functions

1. Protection
2. Support



A line drawing of the human ribcage and upper torso skeleton, showing the ribs, sternum, and vertebrae.

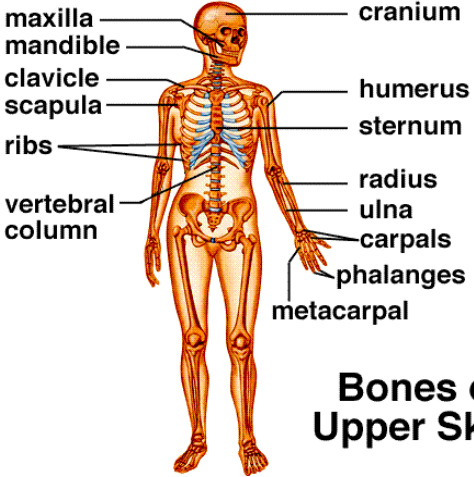
Slide 32

## Appendicular Skeleton

- Shoulders
- Arms
- Hips
- Legs

Slide 33

Sylvia S. Mader, Human Biology, 5th edition. Copyright © 1997 The McGraw-Hill Companies, Inc. All rights reserved.



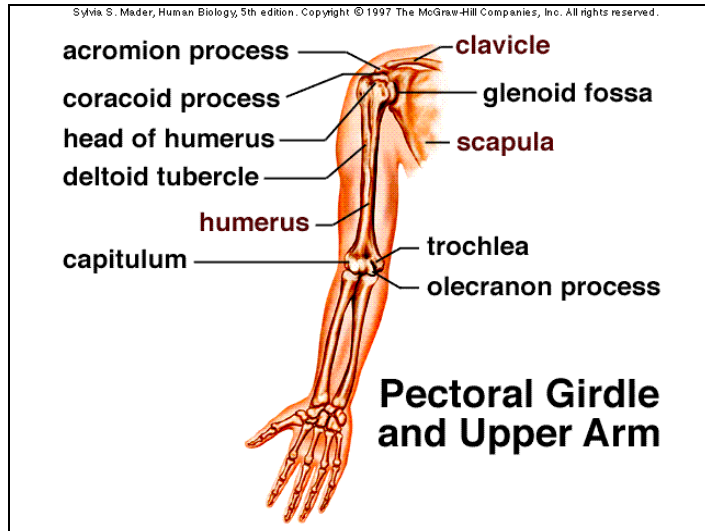
maxilla  
mandible  
clavicle  
scapula  
ribs  
vertebral column

cranium  
humerus  
sternum  
radius  
ulna  
carpals  
phalanges  
metacarpal

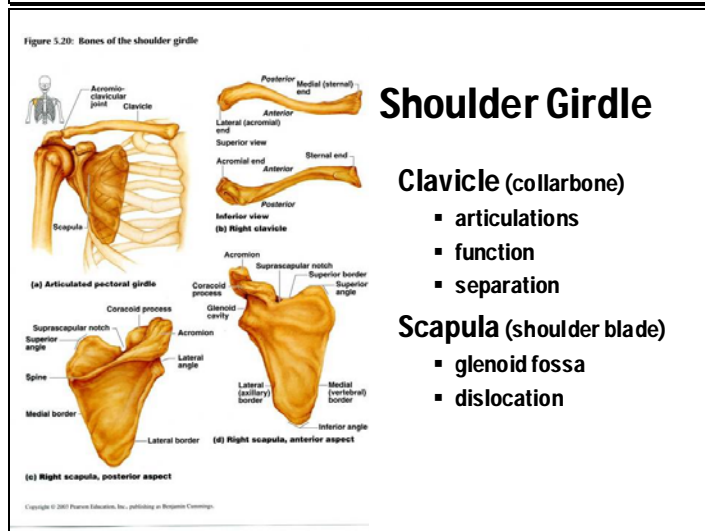
### Bones of the Upper Skeleton

A diagram of a human skeleton with labels for various bones. The labels on the left side are: maxilla, mandible, clavicle, scapula, ribs, and vertebral column. The labels on the right side are: cranium, humerus, sternum, radius, ulna, carpals, phalanges, and metacarpal. The bones of the upper skeleton are highlighted in a darker color.

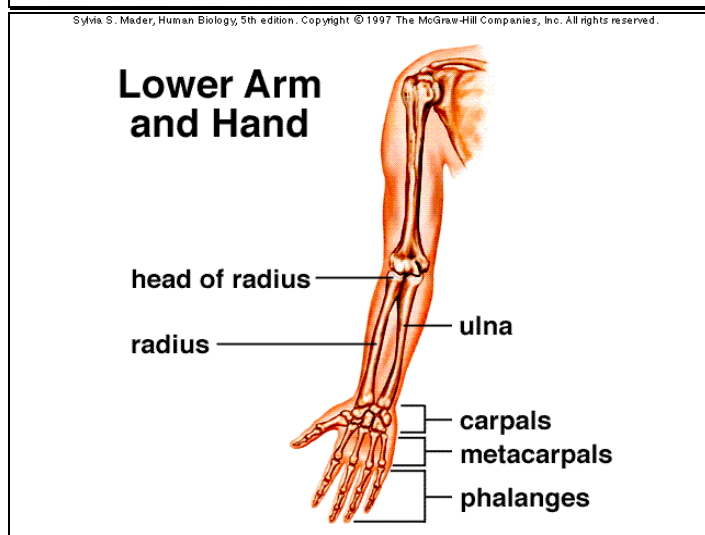
Slide 34



Slide 35



Slide 36



Slide 37

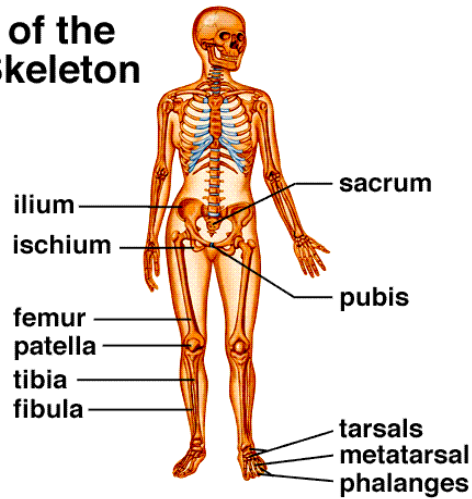
## Shoulder and Arm

- Clavicle - collarbone
- Scapula - shoulder blade
- Humerus - upper arm
- Radius - lateral lower arm (thumb side)
- Ulna - medial lower arm
- Carpals - wrist bones (8)
- Metacarpals - palm bones (knuckles)
- Phalanges - finger bones (14)

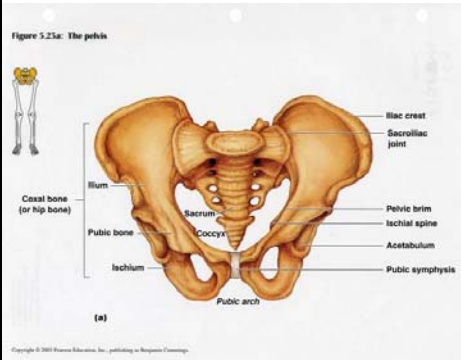
Slide 38

Sylvia S. Mader, Human Biology, 5th edition. Copyright © 1997 The McGraw-Hill Companies, Inc. All rights reserved.

## Bones of the Lower Skeleton



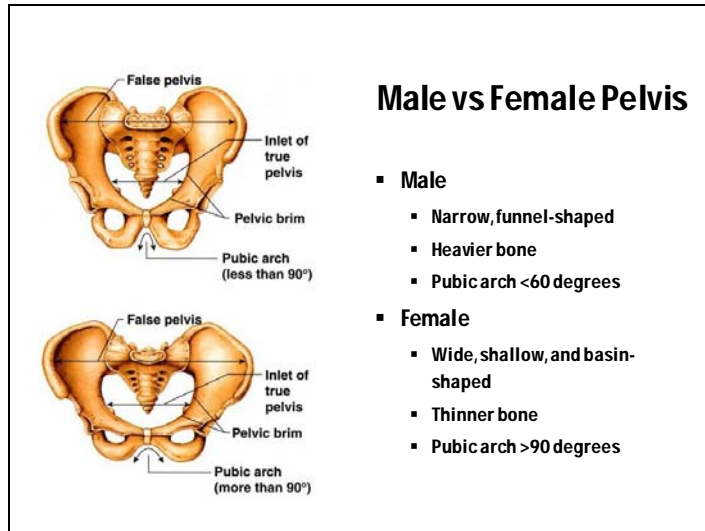
Slide 39



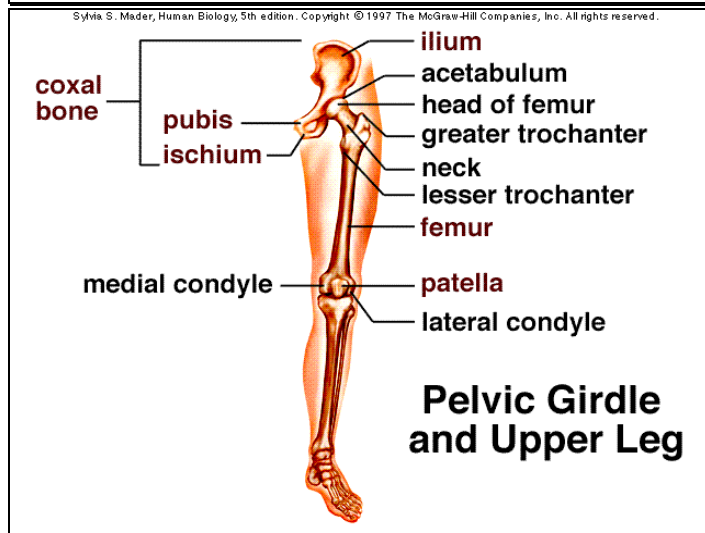
## Pelvis

- Pubic symphysis
- Pubic arch
- Sacrum
- Acetabulum

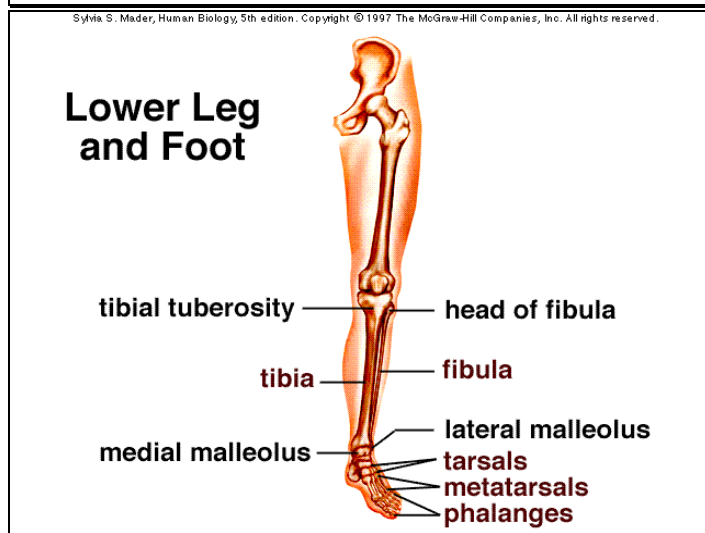
Slide 40



Slide 41



Slide 42



Slide 43

## **Hip and Leg**

- Pelvis - hip bone
- Femur - upper leg
- Patella - kneecap
- Tibia - medial lower leg
- Fibula - lateral lower leg
- Tarsals - ankle bones (7)
- Metatarsals - bones of sole (5)
- Phalanges - toe bones (14)

Slide 44

## **Joints**

### **Functions:**

1. Hold bones together
2. Give skeleton mobility

### **Two classifications of joints:**

1. functional
2. structural

Slide 45

## **Classification of Joints by Function**

### **Three types:**

1. Immovable (synarthroses)
2. Slightly movable (amphiarthroses)
3. Freely movable (diarthroses)

Slide 46

## Classification of Joints by Structure

Three types:

1. **Fibrous joints**
  - sutures of skull
2. **Cartilaginous joints**
  - intervertebral joints
3. **Synovial joints**
  - elbows and knees

Slide 47

Sylvia S. Mader, Inquiry Into Life, 9th edition. Copyright © 1997 The McGraw-Hill Companies, Inc. All rights reserved.

## Knee Joint

The diagram shows a sagittal view of the knee joint. On the left, the biceps femoris muscle and gastrocnemius muscle are shown. On the right, the quadriceps femoris muscle and its tendon are shown. The femur is at the top, and the tibia is at the bottom. The patella is in the center, connected to the femur by the patellar ligament. The joint cavity is between the femur and tibia, containing articular cartilage and a meniscus. A bursa is located between the patella and the femur. The synovial membrane lines the joint cavity.

Labels on the left: biceps femoris muscle, fat, gastrocnemius muscle, meniscus.

Labels on the right: quadriceps femoris muscle, femur, quadriceps tendon, synovial membrane, patella, bursa, joint cavity, cartilage, patellar ligament, tibia.

Knee Replacement <http://www.knee-replacement.com>

Slide 48

## Types of Synovial Joints

- ball & socket
  - hip
- hinge
  - elbow
- pivot
  - atlas and axis
- gliding
  - foot

The diagrams illustrate various synovial joints: (a) Plane joint (Carpals), (b) Hinge joint (Ulna, Humerus), (c) Pivot joint (Ulna, Radius), (d) Gliding joint, (e) Pivot joint, and (f) Ball-and-socket joint (Head of humerus, Scapula). A legend indicates joint types: Nonaxial (red dot), Uniaxial (blue dot), Biaxial (green dot), and Multiaxial (purple dot).

(a) Plane joint: Carpals

(b) Hinge joint: Ulna, Humerus




(c) Pivot joint: Ulna, Radius

(f) Ball-and-socket joint: Head of humerus, Scapula

Slide 49

## Inflammatory Disorders of Joints

- **Arthritis**
  - Osteoarthritis
    - degenerative
  - Gouty arthritis
    - uric acid
  - Rheumatoid arthritis
    - autoimmune



Slide 50

## Osteoporosis



**Normal Bone**                      **Osteoporotic Bone**

Slide 51

**The End**