

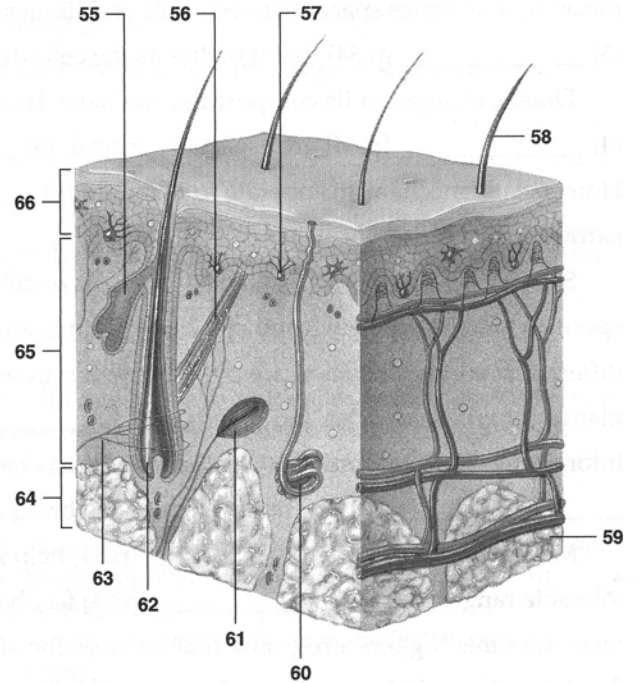
# Integumentary System Lab

Dr. J. Lim

**Labeling** – please note that some locations may have multiple acceptable interpretations

Label the numbered parts of the accompanying illustration.

- 55. \_\_\_\_\_
- 56. \_\_\_\_\_
- 57. \_\_\_\_\_
- 58. \_\_\_\_\_
- 59. \_\_\_\_\_
- 60. \_\_\_\_\_
- 61. \_\_\_\_\_
- 62. \_\_\_\_\_
- 63. \_\_\_\_\_
- 64. \_\_\_\_\_
- 65. \_\_\_\_\_
- 66. \_\_\_\_\_



## Basic Structure of the Skin

Using models, diagrams and study and answer the following:

1. Epidermal layer
  - Are the cells taller in the basal or superficial layer of the epidermis? \_\_\_\_\_
  - Can blood vessels be found in the epidermis? \_\_\_\_\_
  - note how epidermal epithelium extends into dermis to surround the hair follicles
2. Dermal layer
  - The wavy junction (dermal papillae) between the epidermis and dermis is responsible for the presence of \_\_\_\_\_ (ask John Dillinger).
  - has mostly \_\_\_\_\_ connective tissue
  - network of \_\_\_\_\_ and elastic fibers
  - contains \_\_\_\_\_ vessels and a rich \_\_\_\_\_ supply
  - cutaneous gland and hair follicle cells originate in which skin layer? \_\_\_\_\_
  - name the two types of cutaneous glands \_\_\_\_\_ and \_\_\_\_\_
3. Hair follicles
  - How is a hair follicle similar to the epidermal layer of the skin? \_\_\_\_\_

4. Hair

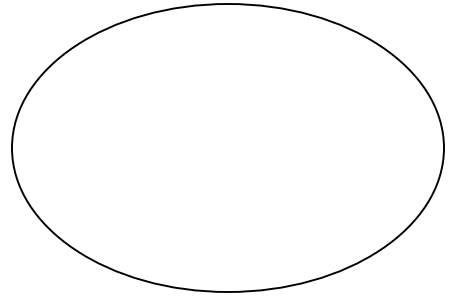
- The bulk of the hair shaft is composed of which material? \_\_\_\_\_

**Activity:**

- Microscopic examination of human scalp

Sketch and label the following (if you can find them)

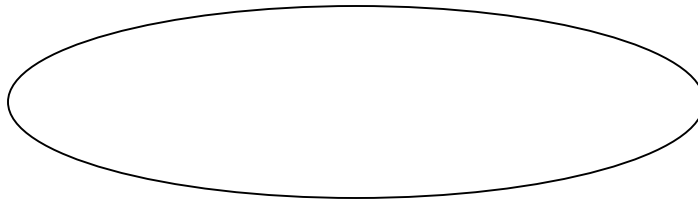
- epidermis (lots of cells)
- dermis (lots of CT)
- hair follicle
- oil/sweat glands
- arrector pili muscle
- subcutaneous fat



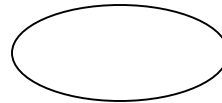
- Microscopic examination of hair

Examine a strand of hair with the compound microscope.

- Carefully remove at least two strands of scalp hair (one light and one dark) from the specimen bags and lay them along the long dimension on a glass slide. Please do not make a mess.
- Add a drop or two of tap water and top it all off with a large cover slip.
- Observe the dark cuticle and lighter cortex of the hair shaft with the 4X objective lens.
- Switch to a highest power objective to view and draw a few overlapping squamous epithelial cells and the cortex.



- If someone is willing to donate hair with “split ends, compare its appearance with undamaged hair. Describe.



5. Sebaceous glands

- exocrine or endocrine? \_\_\_\_\_
- What substance is secreted from a sebaceous gland? \_\_\_\_\_
- Which areas of the skin are devoid of sebaceous glands? \_\_\_\_\_

6. Sweat glands

- exocrine or endocrine? \_\_\_\_\_
- What substances are secreted from sweat glands? \_\_\_\_\_
- Name the two types of sweat glands, their differences and distribution.

---

---

---

---


- Which of the following areas has the greatest density of sweat glands: anterior arm, forehead or anterior leg? \_\_\_\_\_

7. Nails

- The bulk of the nail is composed of which material? \_\_\_\_\_

Identify the nail structures on yourself or your lab partner. **Draw them below.**

- Nail root
- Cuticle
- Lunula
- Body of nail
- Nail fold
- Free edge of nail



**Activities:**

- Dermal Blood Supply
  - Press a hand magnifier against the heel of your hand for a few seconds. Observe and record the color of your skin in the compressed area by looking through the glass.
  - color of compressed skin \_\_\_\_\_
  - What is the reason for the color change? \_\_\_\_\_

- Two-Point Sensibility (need caliper and ruler)
 

The density of touch receptors varies significantly in different areas of the body. Areas with heightened ability to “feel” tend to be those with fine motor control.

  - Using a caliper and a ruler, test the ability of the subject to differentiate two distinct sensations when the skin is touched simultaneously at two points.
    - Have your partner close their eyes. With the caliper arms completely together, gently place the point on the inner surface of the forearm.
    - Gradually increase the distance between the arms, testing the subject’s skin after each adjustment. Continue testing until the subject reports that two points of contact can be felt.
    - This measurement, the smallest distance at which two points of contact can be felt, is the **two-point threshold**.
    - Repeat on the back of the neck and the fingertip.

Body area tested	forearm	neck	fingertip
Two-point threshold (mm)			

Which body area tested has the greatest density of touch receptors?

\_\_\_\_\_

In which layer of the skin do these pressure receptors reside?

\_\_\_\_\_

- Touch Receptor Adaptation (need 4 pennies)

When a stimulus is applied for a prolonged period, the rate of receptor response slows and awareness of the stimulus declines or is lost (**adaptation**) until a stimulus change occurs (ie: clothes on skin).

- With the subject's eyes closed, place a coin on the anterior surface of the forearm. Record the duration of the sensation. \_\_\_\_\_sec
  - Repeat the test, placing the coin at a different forearm location. How long does the sensation persist at the second location? \_\_\_\_\_sec
  - After adaptation at the second site, stack three more coins atop the first one. Does the pressure sensation return? \_\_\_\_\_ If so, for how long is the subject aware of the greater pressure? \_\_\_\_\_sec.
  - Are the same receptors being stimulated when the four coins, rather than one coin, are used? Explain \_\_\_\_\_
-